neurocritical care society Neurocrit Care (2011) 14:407–415
DOI 10.1007/s12028-010-9488-1

ORIGINAL ARTICLE

Acute Ischemic Injury on Diffusion-Weighted Magnetic Resonance Imaging after Poor Grade Subarachnoid Hemorrhage

Katja E. Wartenberg · Sheetal J. Sheth · J. Michael Schmidt · Jennifer A. Frontera · Fred Rincon · Noeleen Ostapkovich · Luis Fernandez · Neeraj Badjatia · E. Sander Connolly · Alexander Khandji · Stephan A. Mayer

Published online: 21 December 2010

Abstract

Background Poor clinical condition is the most important predictor of neurological outcome and mortality after subarachnoid hemorrhage (SAH). Rupture of an intracranial aneurysm was shown to be associated with acute ischemic brain injury in poor grade patients in autopsy studies and small magnetic resonance imaging series.

Methods We performed diffusion-weighted magnetic resonance imaging (DWI) within 96 h of onset in 21 SAH patients with Hunt–Hess grade 4 or 5 enrolled in the Columbia University SAH Outcomes Project between July 2004 and February 2007. We analyzed demographic, radiological, clinical data, and 3 months outcome.

Results Of the 21 patients 13 were Hunt–Hess grade 5, and eight were grade 4. Eighteen patients (86%) displayed bilateral and symmetric abnormalities on DWI, but not on computed tomography (CT). Involved regions included both anterior cerebral artery territories (16 patients), and less often the thalamus and basal ganglia (4 patients), middle (6 patients) or posterior cerebral artery territories (2 patients), or cerebellum (2 patients). At 1-year, 15 patients were dead (life support had been withdrawn in 6), 2 were moderately to severely disabled (modified Rankin Scale [mRS] = 4–5), and 4 had moderate-to-no disability (mRS = 1–3).

Conclusions Admission DWI demonstrates multifocal areas of acute ischemic injury in poor grade SAH patients. These ischemic lesions may be related to transient intracranial circulatory arrest, acute vasoconstriction, microcirculatory disturbances, or decreased cerebral perfusion from neurogenic cardiac dysfunction. Ischemic brain injury in poor grade SAH may be a feasible target for acute resuscitation strategies.

Keywords Subarachnoid hemorrhage · Diffusion-weighted imaging · Magnetic resonance imaging · Ischemic injury

K. E. Wartenberg (✉)
Department of Neurology, Martin-Luther-University Halle-Wittenberg, Ernst-Grube-Strasse 40, 06120 Halle/Saale, Germany
e-mail: katja.wartenberg@medizin.uni-halle.de

S. J. Sheth · J. Michael Schmidt · F. Rincon · N. Ostapkovich · L. Fernandez · S. A. Mayer
Division of Neurocritical Care, Neurological Institute, Columbia University College of Physicians and Surgeons, New York, NY, USA

N. Badjatia · E. Sander Connolly · S. A. Mayer
Department of Neurosurgery, Columbia University College of Physicians and Surgeons, New York, NY, USA

A. Khandji
Department of Radiology, Columbia University College of Physicians and Surgeons, New York, NY, USA

J. A. Frontera
Department of Neurosurgery, Mount Sinai Medical Center, New York, NY, USA

Introduction

Subarachnoid hemorrhage (SAH) is a devastating disease and carries a mortality rate of 20–50% as well as a high rate of cognitive impairment and functional disability among survivors [1, 2]. Death or poor neurological outcome have most consistently been associated with the severity of the neurological deficits on presentation [3, 4], increasing age [3], large aneurysm size [4], rebleeding [5], cerebral infarction from vasospasm [6], and global cerebral

edema [4]. As mortality has decreased in recent years with the advent of improved surgical, endovascular, and critical care techniques, massive brain injury due to a severe initial hemorrhagic event has become the most common cause of death after SAH [7].

Acute ischemic brain injury has not been thought to occur frequently early in the course of SAH. In a CT-based study of 487 SAH patients initially imaged within 72 h of onset, acute infarction was identified in only 17 patients (3%) [8]. Hadeishi et al. performed magnetic resonance (MR) imaging on admission in 32 SAH patients and found no evidence of ischemic injury in 27 good-grade patients. By contrast, they described bilateral multifocal signal abnormalities on diffusion-weighted imaging (DWI) in all 5 of the poor grade (stuporous or comatose) patients studied [9]. These DWI signal abnormalities were often remote from the aneurysm and not consistently associated with corresponding signal abnormalities on T2 or fluid attenuation inversion recovery (FLAIR) sequences. Acute ischemic brain injury has also been observed in animal models of severe SAH [10, 11].

In this study, we sought to further understand the frequency, topography of acute ischemic injury, and outcome of poor grade SAH patients.

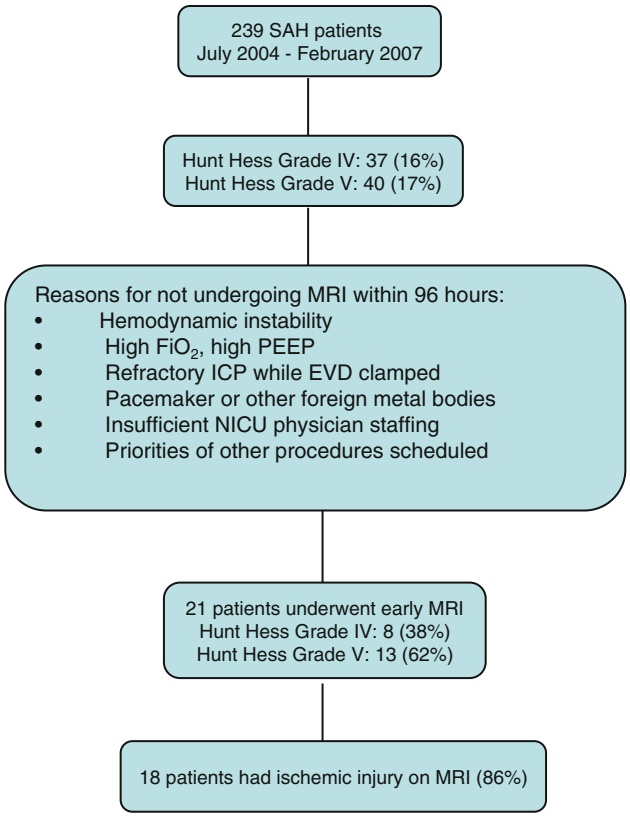

Fig. 1 Patient flow diagram. *SAH* Subarachnoid hemorrhage, *MRI* magnetic resonance imaging, *FiO_2* fraction of inspired oxygen, *PEEP* positive end expiratory pressure, *ICP* intracranial pressure, *EVD* extraventricular drainage, *NICU* neurointensive care unit

Methods

Subjects

All patients described in this report were enrolled in the Columbia University SAH Outcomes Project, a prospective observational outcomes study, that has been in progress since July of 1996. The study was approved by the hospital's Institutional Review Board, and written consent was obtained from the patient or surrogate. The diagnosis of SAH was established by admission CT scan in all cases. In July of 2004, we instituted a policy of routine admission MR imaging for all poor grade (Hunt–Hess grade 4 or 5) patients [12]. Clinical exclusion criteria for performing admission MR are listed in Fig. 1; decisions whether or not to undergo MR scan were made by the attending neurointensivist. Patients included in the present analysis were (1) admitted to Columbia University Medical Center between July 2004 and February 2007, (2) Hunt–Hess grade 4 or 5 on admission, (3) admitted on or before SAH day 3 (day 0 indicates the calendar day of SAH onset), and (4) had an admission MR scan performed. Patients with SAH due to trauma, arteriovenous malformation rupture, or vasculitis were excluded. Details about the clinical management of our patients have been described elsewhere [4].

Clinical Variables

We recorded baseline demographic data and clinical features at onset. A study neurointensivist performed a neurological and general medical evaluation on admission. Neurological status on admission was assessed with the Glasgow Coma Scale (GCS) [13] and the Hunt and Hess scale [12]. We also calculated admission Acute Physiologic and Chronic Health Evaluation II (APACHE II) scores [14], and a physiological subscore by subtracting the GCS, age, and chronic health elements from the total score [15]. Hospital complications and procedures were recorded according to predefined definitions and adjudicated by the entire study team in weekly meetings, as described previously [16].

Radiographic Variables

Admission CT scans were independently evaluated for the presence of acute and chronic cerebral infarction, the amount and location of subarachnoid blood and intraventricular hemorrhage (IVH) [17], the presence and severity of hydrocephalus [18], and presence of focal or global

cerebral edema [4]. We also recorded the location and size of the aneurysm and the presence and extent of vasospasm on admission and follow-up angiograms. MR imaging was performed on a 1.5 T scanner (General Electric) as early as possible. Standard T1, T2, FLAIR, DWI, and apparent diffusion coefficient (ADC) sequences were obtained. Early ischemic injury due to cytotoxic cell damage was defined as the presence of one or more focal hyperintense signal changes confined to a vascular territory or watershed zone on the acute DWI with a corresponding reduction in the ADC map. Hyperintense lesions related to edema from SAH clot or parenchymal hematoma present on the DWI and FLAIR images without corresponding ADC reduction were excluded. All CT and MR scans were reviewed by the study team in a weekly conference. When the etiology, the clinical situation, or complications were unclear, a final diagnosis was made by consensus. These findings were independently evaluated by a neuroradiologist (A.K.) who was blinded to each patient's clinical condition and outcome.

Outcome Assessment

Survival and functional outcome were evaluated by telephone or in-person interview with the modified Rankin Scale (mRS) [19] at 3 and 12 months after hemorrhage.

Statistical Analysis

We analyzed the frequency of demographic, physiological, radiological, and clinical data as well as the 3 months outcome of the patients included. Data analysis was performed with standard statistical software (SPSS Inc, Version 11.0).

Results

Demographic and Clinical Features

During July 2004 and February 2007, 239 patients with SAH were admitted to the Columbia University neurointensive care unit. Of those, 77 patients were rated as Hunt–Hess grade 4 or 5 on admission (Fig. 1). MR was performed in 21 of these patients within 96 h of hemorrhage onset. The reasons for not undergoing early MR imaging are listed in Fig. 1. The median age of the 21 patients was 61 (range, 30–93) years (Table 1). Thirteen patients (62%) were female. Thirteen were Hunt–Hess grade 5 on admission (62%), and eight were grade 4 (38%). Median GCS on admission was 5 (range, 3–10), and median NIHSS was 20 (14–25). Twelve patients experienced a loss of consciousness at symptom onset (57%). The mean APACHE II sub-score on admission was 10.7 ± 3.8. The median SAH day for MR imaging including DWI and FLAIR was day 1 (range day 0–4). In 13 of 21 (62%) patients the MR imaging was performed prior to angiography or an aneurysm repair procedure, whereas in 8 the MR was performed one or more days after the aneurysm had been repaired. There were no reported procedural complications in these patients.

Radiologic Features

The modified Fisher scale was grade 1 (minimal or diffuse thin blood, no IVH) in one patient (5%), grade 2 (minimal or diffuse thin blood, bilateral IVH) in two patients (10%), grade 3 (thick cisternal blood, no IVH) in four patients (19%), and grade 4 (thick cisternal blood, bilateral IVH) in fourteen patients (67%, Table 1). Global cerebral edema was present on the admission CT scan in 13 patients (62%). All patients underwent diagnostic angiography. In eighteen patients an aneurysm was identified, one patient had a left vertebral artery dissection, and in two patients no aneurysm was found.

In eighteen of 21 patients (86%) MR imaging displayed bilateral and symmetric hyperintense signal changes on DWI with corresponding ADC reduction and corresponding signal conversion on FLAIR imaging, without demarcation of ischemic infarction on CT (Fig. 2). These abnormalities most commonly involved the anterior cerebral artery territories (16 patients, 89% of those with ischemic injury), and less commonly the deep middle cerebral artery territories (6 patients, 33%), thalamus and basal ganglia (4 patients, 22%), posterior cerebral artery territory (2 patients, 11%) and cerebellum (2 patients, 11%, Table 1). Cerebral ischemia occurred in a single territory in 2 patients (11%) and in multiple territories in 16 patients (89%).

Hospital Course

Of the 18 aneurysms that were identified, 8 (38%) were treated surgically and 5 (24%) endovascularly with Guglielmi detachable coils. Three patients (14%) experienced early aneurysm rebleeding prior to the repair of the aneurysm. Four patients (19%) presented with acute pulmonary edema and neurogenic stunned myocardium documented by troponin elevation and reduced left ventricular ejection fraction on echocardiography, and 2 patients (10%) had early vasospasm on the initial angiogram.

Three and Twelve Months Outcome

At 3 months, 10 patients had expired (48%); life support was actively withdrawn in 6 of these patients (60%). Ten of the surviving patients were severely disabled at 3 months

Table 1 Clinical characteristics of 21 poor grade SAH patients who underwent admission MR imaging

Pt	Age (years)	Hunt–Hess grade	GCS	LOC at ictus	Aneurysm location	Modified Fisher Scale	APACHE 2 sub-score	Ischemic injury on MR imaging		SAH day of MR imaging	Angiogram and repair procedure (SAH day)	NSM	Global cerebral edema	Early angio spasm	mRS	
								DWI +	ADC +						3 Months	12 Months
1	46	5	4	Yes	L-ICA	4	11	B/L ACA B/L PCA	Same	0	–	–	–	–	6	6
2	62	4	4	Yes	L MCA (>10 mm)	3	9	–	–	1	DSA+ Clipping (day 0)	Yes	Yes	–	5	4
3	93	4	9	–	R MCA	4	10	–	–	1	DSA (day 1)	–	Yes	–	6	6
4	73	4	8	–	L-PCOMM	3	8	R > L ACA	Same	0	DSA/Coiling (day 1)	Yes	Yes	–	5	3
5	68	4	8	Yes	R-PCOMM	4	6	R > L ACA	Same	1	DSA+ Clipping (day 0)	Yes	Yes	–	5	6
6	64	4	4	–	No aneurysm	1	4	R > L ACA	Same	1	DSA (day1)	–	–	–	5	6
7	57	5	5	Yes	R-ACOMM	4	10	B/L ACA, R inferior cerebellar and L superior cerebellar infarcts	Same	3	DSA (day0) + Clipping (day 1)	–	Yes	–	6	6
8	61	5	3	Yes	R-ACOMM	2	13	B/L ACA proximal and distal, L > R	B/L ACA proximal only	3	DSA/Coiling (day 2)	–	–	–	5	6
9	57	4	8	–	L-PCOMM	3	11	L anterior thalamus related to EVD, L MCA	Same	2	DSA+ Clipping (day 1)	–	–	–	5	4
10	58	5	5	–	R-PICA	4	12	–	–	2	DSA/Coiling (day 1)	–	–	–	5	2
11	55	5	3	–	R-ICA (>10 mm)	4	12	R > L ACA proximal and distal, L putamen, R MCA watershed territory	R > L ACA proximal and distal, L putamen	4	DSA (day 1)	–	Yes	–	6	6
12	46	4	10	–	L-ICA (>10 mm)	3	5	B/L ACA proximal and distal	Same	4	DSA+ Clipping (day 1)	–	Yes	–	1	1
13	54	5	4	Yes	R ACA	4	8	L > R ACA, L > R medial temporoparietal, L > R thalamic	L > R ACA and L medial temporoparietal	3	–	–	Yes	–	6	6
14	90	5	7	0	R-PCOMM	4	12	R > L ACA, R anterior thalamic	R anterior thalamic	4	DSA/Coiling (day 1)	–	–	–	6	6
15	64	5	7	1	L ACA	4	7	L ACA	Same	1	DSA+ Clipping (day 1)	–	Yes	–	5	6
16	82	5	4	Yes	A-COMM (>10 mm)	2	13	L > R ACA	Same	2	–	–	–	–	6	6
17	30	5	4	Yes	R MCA (>10 mm)	4	18	R ACA, R MCA, R PCA	Same	1	DSA (day 0) Clipping (day 1)	–	Yes	_	5	6
18	76	5	4	–	No aneurysm	4	12	L MCA, L PCA, R ACA, R MCA	Same	2	DSA (day 2)	–	Yes	_	6	6
19	44	5	5	Yes	L-ACOMM	4	16	L > R ACA, R MCA	Same	1	DSA/Coiling (day 3)	Yes	Yes	Yes	6	6
20	82	4	8	Yes	R-PCOMM	4	8	B/L ACA, L midbrain	Same	1	DSA+ Clipping (day 2)	–	Yes	Yes	6	6

Table 1 continued

Pt	Age (years)	Hunt–Hess grade	GCS	LOC at ictus	Aneurysm location	Modified Fisher Scale	APACHE 2 sub-score	Ischemic injury on MR imaging		SAH day of MR imaging	Angiogram and repair procedure (SAH day)	NSM	Global cerebral edema	Early angio spasm	mRS	
								DWI +	ADC +						3 Months	12 Months
21	59	5	4	Yes	L-VA Dissection	4	19	Splenium of corpus callosum, cerebellar vermis	Same	0	DSA (day 3)	–	Yes	–	5	2

The patients marked with gray color underwent the MRI 1 or more days after aneurysm repair

ADC +: restricted diffusion on apparent diffusion coefficient map

APACHE II sub-score: Acute Physiology and Chronic Health Evaluation Score = (acute physiology score) + (age points) + (chronic health points), physiological subscore by subtracting the GCS, age, and chronic health elements from the total APACHE II score. Scaled 0 = normal, 44 = maximal physiological derangement

DWI +: Hyperintense signal changes on diffusion-weighted imaging

EVD external ventricular drainage, *GCS* Glasgow Coma Scale, *mRS* modified Rankin Score (0 = no deficit, 6 = death), *ICA* internal carotid artery, *ACOMM* anterior communicating artery, *PCOMM* posterior communicating artery, *MCA* middle cerebral artery, *ACA* anterior cerebral artery, *PCA* posterior cerebral artery, *DSA* cerebral digital subtraction angiography

(mRS = 5, 48%), and one patient did not have any significant disability despite symptoms (mRS = 1, 5%). At 12 months, 5 additional patients had died (overall 1-year mortality rate of 71%), 2 patients had moderate-to-severe disability (mRS = 4, 10%), and 4 patients (20%) had mild-to-moderate disability but were able to ambulate independently (mRS = 3, 1 patient; mRS = 2, 2 patients; mRS = 1, 1 patient).

Discussion

Cerebral ischemic injury after rapidly fatal SAH has been described in autopsy studies [20–22], but for the most part this has been considered an unusual phenomenon in the surviving patients. In contrast, our findings indicate that acute diffuse ischemic injury occurs in the majority of poor grade SAH patients. Outcomes were poor in the patients studied; 71% were dead at 1 year. Although 29% of the overall study cohort was alive at 1-year, only two of the 16 patients (12%) with ischemic injury in the anterior cerebral artery territories escaped with a satisfactory outcome.

MR imaging, specifically DWI, has previously been used to diagnose delayed cerebral ischemia from vasospasm [23–25], but few studies have sought to identify ischemic injury during the acute phase of injury. Experimental studies confirm that acute SAH can lead to widespread ischemic injury in the brain. In a study of Wistar rats subjected to SAH, ischemic lesion volume on ADC map increased between 1 and 48 h which was attributed to early vasospasm seen on 3-dimensional MR angiography. Cerebral blood flow (CBF) at 1 h was similar in the SAH and control group, indicating that the brain had been completely reperfused by that point. The localization of the areas of cerebral ischemia was not described [11]. In the study by Busch et al., a rapid ADC decline (85% drop) began within 2 min after SAH in the ipsilateral somatosensory cortex and occurred in all heparinized and non-heparinized rats. These ischemic changes subsequently spread over the ipsilateral and contralateral hemispheres with a 1–3 min delay. The ADC reduction had largely resolved at 2 h after SAH in the non-heparinized group. In the heparinized group a continued decrease of ADC was observed up to 30 min after SAH without recovery, due to continued bleeding [10]. In the MR study of acute human SAH by Hadeishi et al. [9], DWI showed symmetric lesions in multiple vascular territories, most commonly in the midline ACA and medial MCA territories. We found a similar topography of ischemic injury, and this pattern has also been corroborated by autopsy studies [20–22]. In contrast to "watershed" infarction after prolonged hypotension or cardiac arrest, which tends to cause wedge-shaped convexity infarcts on the surface of the brain,

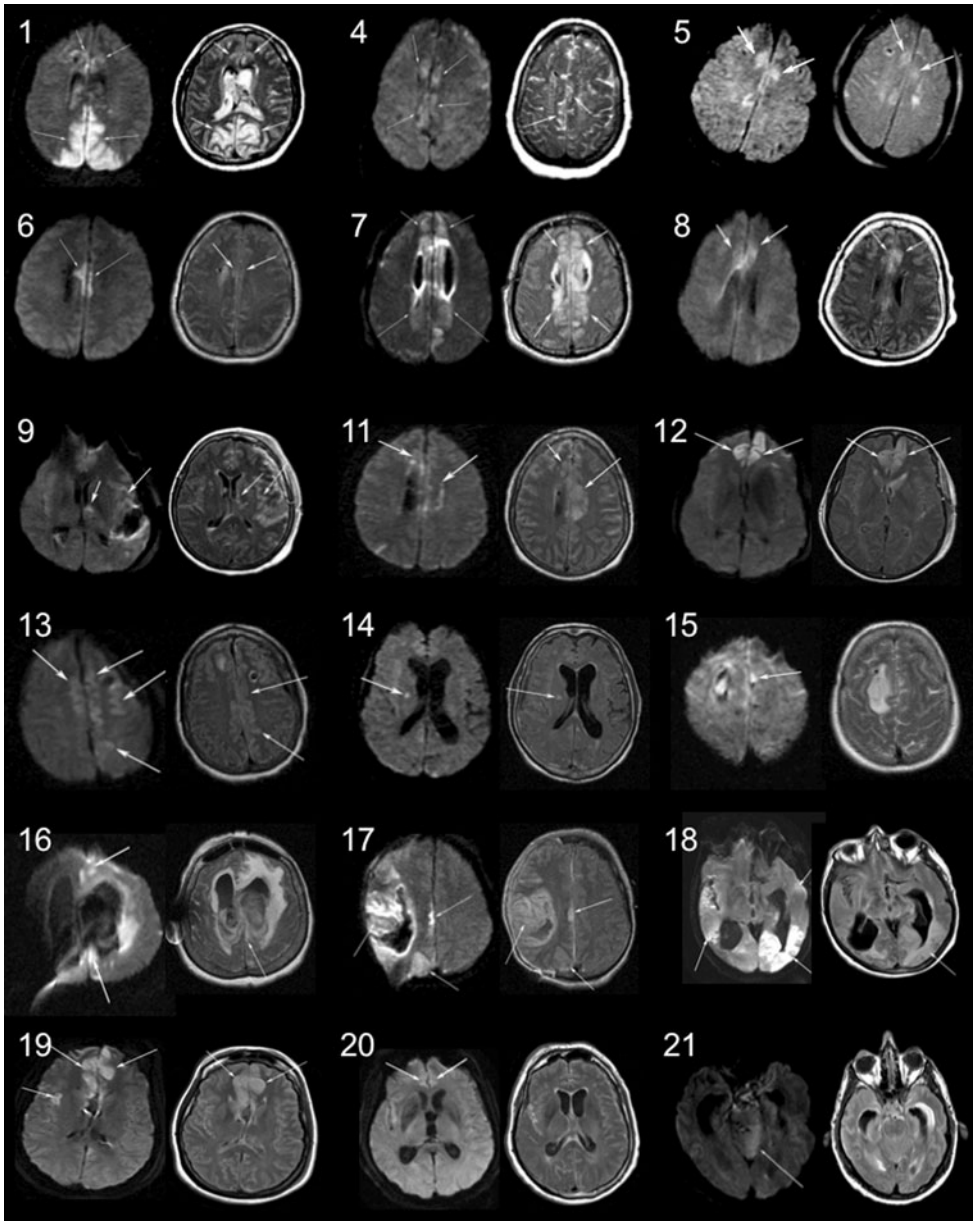

Fig. 2 Representative diffusion-weighted imaging (DWI) and fluid-attenuated inversion recovery imaging (FLAIR) ischemic lesions in 18 poor grade SAH patients with hemorrhage-related ischemic injury. The predominant pattern involved patchy or confluent bilateral ischemic injury involving the anterior cerebral artery territories. In patients 5, 7, 8, 9, 12, 14 imaging was performed in 1 or more days after aneurysm repair

ischemic injury that preferentially occurs in deep midline regions of the brain may reflect a unique pattern of flow-failure that occurs when cerebral perfusion is compromised by a transient but massive increase in intracranial pressure [9, 20]. In a prospectively enrolled cohort of 580 consecutive SAH patients, we found acute cerebral infarction on admission CT in 17 patients (3%), with a higher frequency (10/144, 7%) among Hunt–Hess grade 4 and 5 patients. Six of the 10 poor grade patients (60%) with acute infarction had bilateral and symmetrical pattern of infarction similar to the DWI pattern that we found in our current series [8]. It seems plausible that frank infarction on CT is a "tip-of-the-iceberg" phenomenon that occurs in only the most severe cases of SAH associated with intracranial circulatory arrest. The majority of patients in our present series experienced loss of consciousness and had low GCS scores, high APACHE II physiologic subscores, and global edema on admission CT, derangements that were significantly associated acute infarction in our CT-based study [8].

Global cerebral edema implies a poor prognosis after SAH. It is predicted by loss of consciousness at the onset of SAH, and may be caused by microvascular and reperfusion injury following a massive ICP surge and intracranial circulatory arrest [4]. Intracranial circulatory arrest has been confirmed by cerebral angiography and transcranial Doppler studies during aneurysm rebleeding [26, 27]. Vasomotor paralysis, vasogenic brain edema, increased cerebral blood volume, and intracranial hypertension are

recognized as a general cerebral reflex phenomenon following severe traumatic brain injury and SAH [26, 28]. Microcirculatory dysfunction, loss of blood–brain barrier integrity, induction of cytokines and other inflammatory mediators, endothelial and glial cell activation, intravascular aggregation of erythrocytes and platelets, and shifting of water into the intracellular compartment have all been implicated in the pathogenesis of global brain edema after severe brain injury, but their relative importance after SAH is not known [4, 29–33]. Based on the initial peripheral oxygen saturation and arterial partial pressure of oxygen, none of the patients was hypoxemic upon arrival.

Transient regional or generalized vasospasm at ictus has been documented in humans and animal models during the acute stage of SAH [34–36]. This so called "ultra-early" vasospasm occurs independently of alterations in ICP and CPP [35] and has been associated with delayed cerebral ischemia and poor functional outcome [34–36]. In our study, only two patients had early vasospasm detected on the initial angiogram before aneurysm repair including one patient with an aneurysm of the anterior communicating artery and bilateral ACA infarction who underwent MR imaging before aneurysm coiling. Acute vasoconstriction may have contributed to the development of early ischemic injury in these patients [8, 9].

Neurogenic stunned myocardium occurs as a result of a catecholamine surge from hypothalamic dysfunction during the extreme rise in ICP at ictus [37, 38]. Cardiac dysfunction in conjunction with the subsequent development of pulmonary edema may cause global cerebral hypoperfusion and hypoxia. Four of 21 patients in this study developed neurogenic pulmonary edema and stunned myocardium, as evidenced by reversible echocardiographic left ventricular dysfunction and troponin release. Three of these patients had ischemic injury in the ACA territories, sparing the basal ganglia and thalamus. In the original report by Hadeishi et al., two of the five patients with bilateral DWI abnormalities also had neurogenic stunned myocardium or pulmonary edema [9]. Acute neurogenic cardiopulmonary dysfunction may contribute to the extent and severity of ischemic injury during the acute stage of poor grade SAH.

Spreading depolarization of brain cells in the cerebral cortex, which is associated with microvascular vasoconstriction and may or may not be reversible, has been implicated in the pathogenesis of both acute [10] and delayed [39] cerebral ischemia after SAH. In animal studies spreading depression lasting for only 1–2 min has been linked to the development of MR changes [40], and in human SAH patients spreading depression can last for minutes to hours. Longer lasting depolarizations correlated with worse functional outcome [39]. The DWI abnormalities seen in our patient cohort may in part be a consequence of energy failure related to sustained spreading depolarization.

Limitations of our study include the lack of a uniform, prospective, serial MR imaging protocol, and the fact that we could not perform MR imaging of many poor grade SAH patients due to logistical and patient safety reasons. In the small series reported by Hadeishi et al. [9], DWI abnormalities were noted in different patients to progress or resolve. Serial imaging studies are required to provide more information regarding the dynamics of DWI abnormalities after poor grade SAH which we did not obtain. Only patients considered neurologically and hemodynamically stable could undergo MR scanning according to our protocol, and staffing demands in the ICU served as an important mitigating factor for taking patients to scan. Therefore, our study sample is small and may have been subject to selection bias, since we performed MR imaging in only 27% (21/77) of grade 4 and 5 patients admitted during the study period. Since our bias was toward performing MR imaging in more stable patients, it is possible that the burden of ischemic injury might be even more severe in a more representative population. Serial transcranial Doppler studies were not obtained in the acute phase of SAH. Finally, MR imaging was performed prior to any aneurysm repair procedure in only 62% of the patients. However, the patterns of the ischemic brain injury seen on DWI and FLAIR, mainly including bilateral ACA territories, did not differ between the patients scanned before or after aneurysm repair, and resemble the topography of ischemic injury in CT and autopsy studies [8, 20–22]. Despite this fact, the possibility of procedure-related infarction in one or more of the eight patients who underwent MR imaging after repair of their aneurysm cannot be excluded.

Our findings may point to a new potential target for novel resuscitation and neuroprotection strategies designed to further reduce morbidity and mortality after poor grade SAH. In the modern era of SAH management, severe brain injury related to the acute effects of hemorrhage has become the most important cause of death and disability. Induced hypothermia reduces cerebral ischemic injury and improves outcome after cardiac arrest [41], and shows promise as an intervention to test in future studies. Hypertonic saline has been shown to reduce intracranial pressure and cerebrovascular resistance and improve CBF after poor grade SAH [42], and might be a promising therapy as well. Before studies of this nature can proceed, however, there is a need for more systematic and comprehensive studies detailing the natural history and dynamics of DWI-detected ischemic injury after SAH, and to clarify the potential role of cardiopulmonary dysfunction in the pathogenesis of this disorder.

References

1. Kreiter KT, Copeland D, Bernardini GL, Bates JE, Peery S, Claassen J, Du YE, Stern Y, Connolly ES, Mayer SA. Predictors of cognitive dysfunction after subarachnoid hemorrhage. Stroke. 2002;33:200–8.
2. Mayer SA, Kreiter KT, Copeland D, Bernardini GL, Bates JE, Peery S, Claassen J, Du YE, Connolly ES Jr. Global and domain-specific cognitive impairment and outcome after subarachnoid hemorrhage. Neurology. 2002;59:1750–8.
3. Lagares A, Gomez PA, Lobato RD, Alen JF, Alday R, Campollo J. Prognostic factors on hospital admission after spontaneous subarachnoid haemorrhage. Acta Neurochir. 2001;143:665–72.
4. Claassen J, Carhuapoma JR, Kreiter KT, Du EY, Connolly ES, Mayer SA. Global cerebral edema after subarachnoid hemorrhage: frequency, predictors, and impact on outcome. Stroke. 2002; 33:1225–32.
5. Naidech AM, Janjua N, Kreiter KT, Ostapkovich ND, Fitzsimmons BF, Parra A, Commichau C, Connolly ES, Mayer SA. Predictors and impact of aneurysm rebleeding after subarachnoid hemorrhage. Arch Neurol. 2005;62:410–6.
6. Kassell NF, Torner JC, Haley EC Jr, Jane JA, Adams HP, Kongable GL. The international cooperative study on the timing of aneurysm surgery. Part 1: overall management results. J Neurosurg. 1990;73:18–36.
7. Broderick JP, Brott TG, Duldner JE, Tomsick T, Leach A. Initial and recurrent bleeding are the major causes of death following subarachnoid hemorrhage. Stroke. 1994;25:1342–7.
8. Schmidt JM, Rincon F, Fernandez A, Resor C, Kowalski RG, Claassen J, Connolly ES, Fitzsimmons BF, Mayer SA. Cerebral infarction associated with acute subarachnoid hemorrhage. Neurocrit Care. 2007;7:10–7.
9. Hadeishi H, Suzuki A, Yasui N, Hatazawa J, Shimosegawa E. Diffusion-weighted magnetic resonance imaging in patients with subarachnoid hemorrhage. Neurosurgery. 2002;50:741–7.
10. Busch E, Beaulieu C, de Crespigny A, Moseley ME. Diffusion MR imaging during acute subarachnoid hemorrhage in rats. Stroke. 1998;29:2155–61.
11. van den Bergh WM, Schepers J, Veldhuis WB, Nicolay K, Tulleken CA, Rinkel GJ. Magnetic resonance imaging in experimental subarachnoid haemorrhage. Acta Neurochir. 2005;147: 977–83.
12. Hunt WE, Hess RM. Surgical risk as related to time of intervention in the repair of intracranial aneurysms. J Neurosurg. 1968;28:14–20.
13. Teasdale G, Jennett B. Assessment of coma and impaired consciousness. A practical scale. Lancet. 1974;2:81–4.
14. Knaus WA, Draper EA, Wagner DP, Zimmerman JE. APACHE II: a severity of disease classification system. Crit Care Med. 1985;13:818–29.
15. Claassen J, Vu A, Kreiter KT, Kowalski RG, Du EY, Ostapkovich N, Fitzsimmons BF, Connolly ES, Mayer SA. Effect of acute physiologic derangements on outcome after subarachnoid hemorrhage. Crit Care Med. 2004;32:832–8.
16. Wartenberg KE, Schmidt JM, Claassen J, Temes RE, Frontera JA, Ostapkovich N, Parra A, Connolly ES, Mayer SA. Impact of medical complications on outcome after subarachnoid hemorrhage. Crit Care Med. 2006;34:617–23. quiz 624.
17. Hijdra A, van Gijn J, Nagelkerke NJ, Vermeulen M, van Crevel H. Prediction of delayed cerebral ischemia, rebleeding, and outcome after aneurysmal subarachnoid hemorrhage. Stroke. 1988;19: 1250–6.
18. van Gijn J, Hijdra A, Wijdicks EF, Vermeulen M, van Crevel H. Acute hydrocephalus after aneurysmal subarachnoid hemorrhage. J Neurosurg. 1985;63:355–62.
19. Lyden PD, Lau GT. A critical appraisal of stroke evaluation and rating scales. Stroke. 1991;22:1345–52.
20. Crompton MR. The pathogenesis of cerebral infarction following the rupture of cerebral berry aneurysms. Brain. 1964;87:491–510.
21. Birse SH, Tom MI. Incidence of cerebral infarction associated with ruptured intracranial aneurysms. A study of 8 unoperated cases of anterior cerebral aneurysm. Neurology. 1960;10:101–6.
22. Smith B. Cerebral pathology in subarachnoid haemorrhage. J Neurol Neurosurg Psychiatry. 1963;26:535–9.
23. Phan TG, Huston J 3rd, Campeau NG, Wijdicks EF, Atkinson JL, Fulgham JR. Value of diffusion-weighted imaging in patients with a nonlocalizing examination and vasospasm from subarachnoid hemorrhage. Cerebrovasc Dis. 2003;15:177–81.
24. Liu Y, Soppi V, Mustonen T, Kononen M, Koivisto T, Koskela A, Rinne J, Vanninen RL. Subarachnoid hemorrhage in the subacute stage: elevated apparent diffusion coefficient in normal-appearing brain tissue after treatment. Radiology. 2007;242: 518–25.
25. Weidauer S, Lanfermann H, Raabe A, Zanella F, Seifert V, Beck J. Impairment of cerebral perfusion and infarct patterns attributable to vasospasm after aneurysmal subarachnoid hemorrhage: a prospective MRI and DSA study. Stroke. 2007;38:1831–6.
26. Grote E, Hassler W. The critical first minutes after subarachnoid hemorrhage. Neurosurgery. 1988;22:654–61.
27. Bergquist E, Bergstrom K. Angiographic documentation of the development of cerebral circulatory arrest. Acta Radiol Diagn. 1972;12:7–11.
28. Krasznai L, Grote EH. Acute vasoparalysis after subarachnoid haemorrhage and cerebral trauma: general reflex phenomenon? Neurol Res. 1994;16:40–4.
29. Shigeno T, Fritschka E, Brock M, Schramm J, Shigeno S, Cervos-Navarro J. Cerebral edema following experimental subarachnoid hemorrhage. Stroke. 1982;13:368–79.
30. Kuyama H, Ladds A, Branston NM, Nitta M, Symon L. An experimental study of acute subarachnoid haemorrhage in baboons: changes in cerebral blood volume, blood flow, electrical activity and water content. J Neurol Neurosurg Psychiatry. 1984;47:354–64.
31. Kamiya K, Kuyama H, Symon L. An experimental study of the acute stage of subarachnoid hemorrhage. J Neurosurg. 1983;59: 917–24.
32. Sehba FA, Mostafa G, Friedrich V Jr, Bederson JB. Acute microvascular platelet aggregation after subarachnoid hemorrhage. J Neurosurg. 2005;102:1094–100.
33. Ohkuma H, Manabe H, Tanaka M, Suzuki S. Impact of cerebral microcirculatory changes on cerebral blood flow during cerebral vasospasm after aneurysmal subarachnoid hemorrhage. Stroke. 2000;31:1621–7.
34. Qureshi AI, Sung GY, Suri MA, Straw RN, Guterman LR, Hopkins LN. Prognostic value and determinants of ultra-early angiographic vasospasm after aneurysmal subarachnoid hemorrhage. Neurosurgery. 1999;44:967–73.
35. Bederson JB, Levy AL, Ding WH, Kahn R, DiPerna CA, Jenkins AL 3rd, Vallabhajosyula P. Acute vasoconstriction after subarachnoid hemorrhage. Neurosurgery. 1998;42:352–60.
36. Baldwin ME, Macdonald RL, Huo D, Novakovic RL, Goldenberg FD, Frank JI, Rosengart AJ. Early vasospasm on admission angiography in patients with aneurysmal subarachnoid hemorrhage is a predictor for in-hospital complications and poor outcome. Stroke. 2004;35:2506–11.
37. Mayer SA, Fink ME, Homma S, Sherman D, LiMandri G, Lennihan L, Solomon RA, Klebanoff LM, Beckford A, Raps EC. Cardiac injury associated with neurogenic pulmonary edema following subarachnoid hemorrhage. Neurology. 1994;44: 815–20.

38. Tung P, Kopelnik A, Banki N, Ong K, Ko N, Lawton MT, Gress D, Drew B, Foster E, Parmley W, Zaroff J. Predictors of neurocardiogenic injury after subarachnoid hemorrhage. Stroke. 2004; 35:548–51.
39. Dreier JP, Woitzik J, Fabricius M, Bhatia R, Major S, Drenckhahn C, Lehmann TN, Sarrafzadeh A, Willumsen L, Hartings JA, Sakowitz OW, Seemann JH, Thieme A, Lauritzen M, Strong AJ. Delayed ischaemic neurological deficits after subarachnoid haemorrhage are associated with clusters of spreading depolarizations. Brain. 2006;129:3224–37.
40. Latour LL, Hasegawa Y, Formato JE, Fisher M, Sotak CH. Spreading waves of decreased diffusion coefficient after cortical stimulation in the rat brain. Magn Reson Med. 1994;32:189–98.
41. Mild therapeutic hypothermia to improve the neurologic outcome after cardiac arrest. N Engl J Med. 2002;346:549–56.
42. Tseng MY, Al-Rawi PG, Pickard JD, Rasulo FA, Kirkpatrick PJ. Effect of hypertonic saline on cerebral blood flow in poor-grade patients with subarachnoid hemorrhage. Stroke. 2003;34:1389–96.